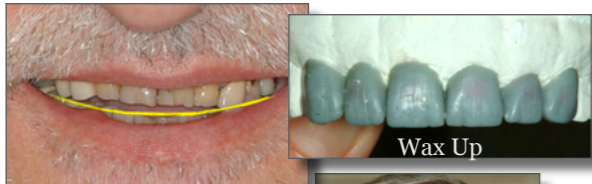

IN A NUTSHELL

My dad's reconstruction was based on restoring severe end-to-end dental wear. I started by evaluating the smile to determine a new incisal edge length, tried this mock up in the face, and once happy, built the posterior teeth up to an occlusal plane that would match. This meant opening up his vertical dimension of occlusion, which would also reduce the end-on occlusion and force him to be more class II.



Wax Up



Before



MockUp

We started November 2013 removing existing posterior full coverage restorations to confirm solid foundations beneath. Then we jumped his occlusion to the new vertical dimension in temporaries. Once that was confirmed to be stable, final restorations were placed in June 2015. A more detailed history of his treatment in the prior newsletters is available on my website under the ProbeTips page.

Copyright 2022 Dr. Pamela Nicoara

PHASED FULL MOUTH RECONSTRUCTION

Seven years ago I presented my dad's full mouth reconstruction case as a means of sharing the idea that opportunities are available to each of us to enhance the lives of our patients by pursuing knowledge beyond our basic dental school training.

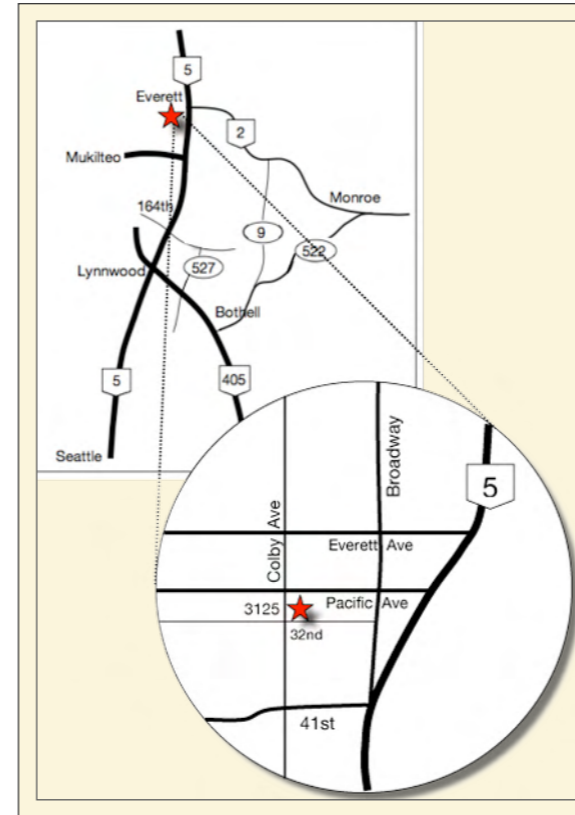
The path I chose was through Spear Education, created by Dr. Frank Spear. Dr. Spear, a prosthodontist in Seattle, has a continuing education facility in Scottsdale, Arizona. It is a state of the art teaching 'Mecca' with hands-on laboratory and clinical areas, in addition to a lecture auditorium, and catered breakfast and lunch. Dr. Spear shares the lessons he's learned over his years of private practice in a way that makes hard to understand concepts manageable, and hard to achieve outcomes attainable. I took their lecture and hands on courses: a continuum of 7 trips of 3-4 days at a time over the course two years to build the knowledge and confidence to help my dad.

Regardless of whether it is Spear or Kois or whichever higher end courses you can take, I hope you each will consider learning more about advanced continuing education opportunities in order to enhance your lives and the lives of your patients.

Below is a timeline of events since cementation of his final crowns, and considerations for what could have been done differently with the benefit of hindsight. I hope you will enjoy this continuing follow-up story!

Pamela A Nicoara DDS MSD PLLC

PERIODONTOLOGY IMPLANTOLOGY ORAL MEDICINE



3125 Colby Avenue, Suite H
Everett WA 98201
T: 425-374-5380 F: 425-374-5382

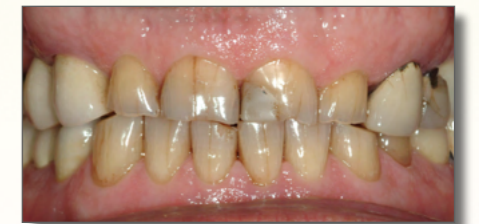www.NICOARaperio.com
doctor@NICOARaperio.com

PROBE TIPS

A QUARTERLY PERIODONTAL
NEWSLETTER

BY PAMELA NICOARA DDS MSD

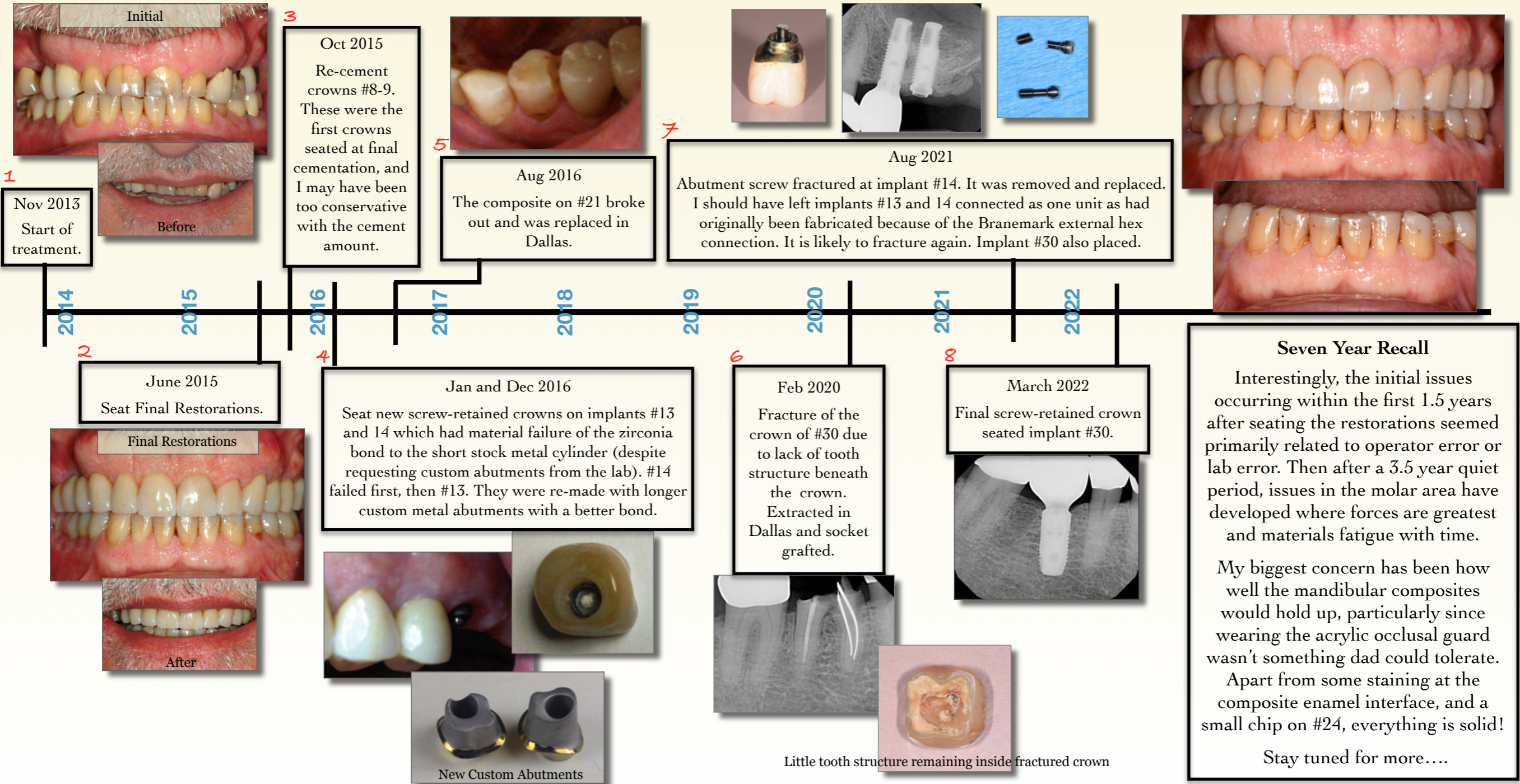
Full Mouth Reconstruction Seven Year Recall



VOLUME 15, No. 1

MAY 2022

Phased Full Mouth Reconstruction



Seven Year Recall

Interestingly, the initial issues occurring within the first 1.5 years after seating the restorations seemed primarily related to operator error or lab error. Then after a 3.5 year quiet period, issues in the molar area have developed where forces are greatest and materials fatigue with time.

My biggest concern has been how well the mandibular composites would hold up, particularly since wearing the acrylic occlusal guard wasn't something dad could tolerate.

Apart from some staining at the composite enamel interface, and a small chip on #24, everything is solid!

Stay tuned for more....